

Progressive Structural Brain Abnormalities and Their Relationship to Clinical Outcome

A Longitudinal Magnetic Resonance Imaging Study Early in Schizophrenia

Beng-Choon Ho, MRCPsych; Nancy C. Andreasen, MD, PhD; Peg Nopoulos, MD; Stephan Arndt, PhD; Vincent Magnotta, PhD; Michael Flaum, MD

Background: Many studies have shown that structural brain abnormalities in schizophrenia are already present by the time of index evaluation of first-episode patients. However, whether these abnormalities progressively worsen during the subsequent course of the disorder remains unresolved.

Methods: To study the longitudinal progression of structural brain abnormalities, high-resolution multispectral magnetic resonance images obtained on 73 recent-onset schizophrenic patients and 23 controls were analyzed using state-of-the-art, well-validated, and highly reliable neuroimaging tools. The mean duration between initial and follow-up MRIs was 3 years. Repeated-measures analysis of covariance was carried out to determine (1) whether brain volume changes differed between patients and controls and (2) the significance of regional brain changes on functional outcome in schizophrenia.

Results: We found accelerated enlargement in cortical sulcal cerebrospinal fluid spaces early in the course of schizophrenia. Instead of the usual trajectory of volume

enlargement, patients showed progressive reduction in frontal lobe white matter volume. A reciprocal increase in frontal lobe cerebrospinal fluid volume also occurred at a more rapid rate in patients than in controls. In keeping with most of our a priori hypotheses, patients with poor outcome had greater lateral ventricular enlargement over time than patients with good outcome. Progressive decrement in frontal lobe white matter volume and enlargement in frontal lobe cerebrospinal fluid volume were associated with greater negative symptom severity. Reductions in frontal lobe gray and white matter volumes correlated with poorer executive functioning.

Conclusions: There are ongoing changes in the brains of schizophrenic patients during the initial years after diagnosis despite ongoing antipsychotic drug treatment. These progressive changes seem to be most evident in the frontal lobes and to correlate with functional impairment. Disruptions in neurodevelopment or neural plasticity may act alone or in combination to bring about these progressive brain deficits in schizophrenia.

Arch Gen Psychiatry. 2003;60:585-594

From the Mental Health Clinical Research Center, Iowa City, Iowa (Drs Ho, Andreasen, Nopoulos, Arndt, Magnotta, and Flaum); the Department of Psychiatry, University of Iowa College of Medicine, Iowa City (Drs Ho, Andreasen, Nopoulos, Arndt, and Flaum); and The MIND Institute and the Department of Psychiatry, University of New Mexico, Albuquerque (Dr Andreasen).

IN VIVO neuroimaging has provided compelling evidence for structural¹⁻³ and functional^{4,5} brain abnormalities in schizophrenia. Findings of enlarged lateral ventricles, third ventricles, and cortical sulcal cerebrospinal fluid (CSF) spaces; reductions in medial temporal lobe structures and frontal lobes; and abnormalities in subcortical structures have been replicated fairly consistently in many magnetic resonance imaging (MRI) studies.³ However, except for the association between poor outcome and enlarged lateral ventricles, the significance of the other commonly replicated brain abnormalities on functional outcome in schizophrenia remains uncertain.⁶ Furthermore, the onset and longitudinal evolution of these anomalies

during the course of schizophrenia have not been well characterized.

Ascertaining the onset of structural brain abnormalities in schizophrenia is difficult because there are currently no methods to efficiently identify and study individuals before overt onset of the disorder. Healthy relatives of schizophrenic patients have brain volumes that are intermediate between patients and controls, suggesting that structural brain abnormalities may be a vulnerability marker and a function of genetic load.⁷⁻¹³ By the time patients first seek treatment, differences in brain volumes between schizophrenic patients and healthy individuals are already evident.^{3,14} Whether there are progressive brain changes after the onset of schizophrenia remains a topic of debate. Determining whether neural changes con-

tinue during the course of the illness is important for understanding its neurobiological features. Determining whether neural changes continue also has implications for the treatment of schizophrenia. New and more effective treatments will need to be developed if progression occurs despite current treatments.

Perhaps the most robust method to ascertain whether there are progressive neural changes in schizophrenia is through within-subject longitudinal neuroimaging studies. However, such prospective studies are particularly challenging to perform, given the difficulties associated with getting patients and control subjects to return for additional MRIs and the rapid advances in neuroimaging technology. Hence, most longitudinal morphometric MRI studies to date have relatively small sample sizes, use thick, noncontiguous slices that provide poor anatomic resolution, or both.

As a result, findings from these longitudinal neuroimaging studies of schizophrenic patients have been mixed. Early longitudinal computerized tomographic studies (eg, Nasrallah et al¹⁵) have failed to find progressive enlargement in ventricular size after the onset of schizophrenia. However, more recent longitudinal MRI studies of first-episode patients,¹⁶⁻²⁰ chronic patients,²¹ and childhood-onset patients²²⁻²⁷ seem to provide increasingly convergent evidence that structural brain deficits in schizophrenia may be progressive.

We report herein the results of the largest longitudinal MRI study of schizophrenia conducted to date, to our knowledge, using well-validated and highly reliable state-of-the-art neuroimaging tools. The aims of this study are (1) to determine whether brain volume changes early in the course of schizophrenia differ from the usual age-related trajectory and (2) to determine how brain volume changes may relate to functional outcome in schizophrenia. We measured regional brain volumes during an average of 3 years using high-resolution MRI in a large cohort of schizophrenic patients, many of whom were neuroleptic naive and in the midst of their first episode at the time of initial MRI. These patients were compared with a matched group of control subjects who also underwent serial MRI during the same time. Based on previous longitudinal neuroimaging studies,^{17,18,28} we hypothesized that (1) greater lateral ventricular enlargement would be associated with poorer outcome in schizophrenia, (2) patients with greater severity of negative symptoms would show greater reductions in frontal lobe volumes over time, (3) severity of psychotic symptoms during follow-up would correlate with longitudinal reductions in temporal lobe volumes, and (4) poor executive functioning at follow-up would be associated with progressive decrement in frontal lobe volumes.

METHODS

PARTICIPANTS

The study protocol was reviewed and approved by the University of Iowa institutional review board. Seventy-three patients (53 males and 20 females) and 23 control subjects (15 males and 8 females) were recruited through the University of Iowa Mental Health Clinical Research Center. All patients had a

DSM-IV diagnosis of schizophrenia and were assessed early in the course of schizophrenia with little confounding illness chronicity or previous antipsychotic drug treatment at the time of initial MRI. Forty-one patients (56%) were in the midst of their first psychiatric hospitalization. Thirty-three patients (45%) were neuroleptic naive. The median duration of illness (measured from onset of the first psychiatric symptoms) was 2.0 years (25th and 75th interquartile range, 3.0 years). The median duration of cumulative lifetime antipsychotic drug treatment for the whole patient sample at the time of initial MRI was only 1.0 month (25th and 75th interquartile range, 7.0 months). The clinical characteristics of the patient sample, subdivided by whether they were in the midst of their first psychiatric hospitalization, are summarized in **Table 1**.

Controls were recruited from the community through newspaper advertisements and were screened using an abbreviated version of the Comprehensive Assessment of Symptoms and History (CASH).²⁹ Controls were excluded if they had current or past medical, neurological, or psychiatric illnesses. Patient and control groups were comparable with regard to sex, parental socioeconomic status, height, and duration between initial and follow-up MRI (**Table 2**). Controls were significantly older than patients at initial MRI (mean age difference, 2.38 years; $T_{94}=2.06$; $P=.04$). Intake and follow-up MRIs were separated by approximately 3 years. The difference in the mean inter-MRI interval between patients and controls (36 days) was not statistically significant ($T_{94}=0.27$; $P=.79$). All MRIs were obtained between January 1, 1991, and December 31, 2001. The distribution for the year in which MRIs were obtained did not differ significantly between patients and controls ($P=.93$ by Fisher exact test).

INTAKE AND OUTCOME ASSESSMENTS

Seventy of the 73 patients in the study were participants in the larger, ongoing Iowa Prospective Longitudinal Study of Recent-Onset Psychoses.³⁰ The method for selecting and assessing patients has been previously described.³⁰ At the time of initial MRI, all patients undergo an extensive evaluation, which includes phenomenological assessment (symptoms, family history, and obstetric complications), neurological examination, a neuropsychological battery, and morphometric MRI of the brain. Two structured interview instruments—the CASH and the *Psychiatric Status You Currently Have—Baseline Version (PSYCH-BASE)*³¹—are used for clinical assessment. The *Scale for Assessment of Negative Symptoms*³² and the *Scale for Assessment of Positive Symptoms*³³ form part of the CASH and the PSYCH-BASE. Psychiatric diagnoses are based on the CASH. In addition to interviews with the patients, supplemental information is obtained from collateral sources, including family members and previous medical records.

After intake assessment, participants are evaluated at 6-month intervals with longitudinal follow-up versions of the CASH and the PSYCH-BASE to develop a retrospective timeline of the severity of symptoms (weekly ratings) and treatment during the preceding 6 months. Additional collateral information is obtained from a family member and available medical records to complete the retrospective timeline. At the 2-, 5-, 9-, and 12-year follow-up evaluations, the extensive assessments performed at intake are repeated, including MRI of the brain and the neuropsychological battery. Data on outcome and treatment during the inter-MRI period were unavailable for the 3 patients who were not participants in this longitudinal study.

Four measures of outcome were examined. Patients were categorized as having poor outcome if they did not achieve remission of positive symptoms in the 6 months preceding follow-up MRI. Remission was operationalized as 8 consecutive

Table 1. Clinical Characteristics of 73 Schizophrenic Patients

Characteristic	First Hospitalization (n = 41)	Not First Hospitalization (n = 32)	Total (N = 73)
At initial MRI*			
Age at onset of first psychiatric symptoms, mean (SD), y	21.2 (4.87)	21.9 (4.50)	21.5 (4.69)
Age at first outpatient psychiatric treatment, mean (SD), y	23.0 (5.46)	22.6 (4.67)	22.8 (5.10)
Age at first psychiatric hospitalization, mean (SD), y	24.1 (5.02)	22.8 (4.54)	23.5 (4.83)
Previous psychiatric hospitalizations, mean No. (IQR)	0	2.6 (2.59)	1.2 (2.11)
Duration of illness since first psychiatric symptoms, median (IQR), y	2.0 (4.0)	3.0 (2.5)	2.0 (3.0)
Duration of previous antipsychotic drug treatment, median (IQR), mo	1.0 (1.0)	8.0 (19.5)	1.0 (7.0)
During the inter-MRI interval†			
Substantial positive symptoms, mean (SD), wk/y‡	19.8 (19.59)	26.0 (22.86)	22.5 (21.12)
Substantial negative symptoms, mean (SD), wk/y§	43.7 (13.13)	40.6 (16.62)	42.4 (16.69)
Positive symptom severity, mean (SD)	4.1 (2.61)	5.3 (3.53)	4.6 (3.07)
Negative symptom severity, mean (SD)¶	8.9 (2.75)	8.2 (2.94)	8.6 (2.83)

Abbreviations: IQR, 25th and 75th interquartile range; MRI, magnetic resonance imaging.

*No statistically significant differences between patients in the midst of their first psychiatric hospitalization and those not in their first hospitalization ($T_{71} \leq 1.18$; $P \geq .24$, except for number of previous hospitalizations and previous antipsychotic drug treatment: $T_{71} \geq 4.57$; $P < .001$).

†No statistically significant differences between patients in the midst of their first psychiatric hospitalization and those not in their first hospitalization ($T_{68} \leq 1.59$; $P \geq .12$).

‡Severity of 3 or more on any one of the positive symptom global ratings (delusions, hallucinations, formal thought disorder, bizarre behavior, and inappropriate affect).

§Severity of 3 or more on any one of the negative symptom global ratings (alogia, anhedonia, avolition, and affective flattening).

||Sum of global ratings on 5 positive symptoms.

¶Sum of global ratings on 4 negative symptoms.

Table 2. Demographic Characteristics of 23 Control Subjects and 73 Schizophrenic Patients

Characteristic	Controls (n = 23)	Patients (n = 73)	Statistics
Males, No. (%)	15 (65)	53 (73)	$\chi^2_{1} = 0.46$; $P = .50$
Parental socioeconomic status, mean (SD)*	2.96 (0.37)	2.92 (0.76)	$T_{78.1} = 0.33$; $P = .74$
Height, mean (SD), cm	174.1 (9.08)	174.3 (9.52)	$T_{94} = 0.09$; $P = .93$
Age at initial MRI, mean (SD) [range], y	26.9 (5.30) [16-35]	24.5 (4.67) [16-35]	$T_{94} = 2.06$; $P = .04$
Duration of inter-MRI interval, mean (SD) [range], y	3.39 (1.60) [0.92-6.67]	3.29 (1.48) [1.12-6.25]	$T_{94} = 0.27$; $P = .79$

Abbreviation: MRI, magnetic resonance imaging.

*Modified Hollingshead scale.⁸⁰

weeks during which all 5 positive symptoms were no worse than mild severity (≤ 2 on global ratings of delusions, hallucinations, positive formal thought disorder, bizarre behavior, and inappropriate affect). Patients who met the criteria for positive symptom remission were categorized as having good outcome. Severity of negative symptoms was the mean weekly ratings of the sum of alogia, anhedonia, avolition, and affective flattening global ratings during the inter-MRI interval. Similarly, severity of positive symptoms was the mean weekly ratings of the sum of the 5 positive symptom global ratings during the inter-MRI interval. Executive functioning was the summed z score average of 7 variables from the neuropsychological battery administered at the time of follow-up MRI. The 7 component tests were number of categories attained and number of preservative errors on the Wisconsin Card Sorting Test; the abstractions subtest of the Shipley Institute of Living Scale; and the comprehension, similarities, picture completion, and picture arrangement subtests of the Wechsler Adult Intelligence Scale-Revised. This theoretical grouping of tests to measure executive functioning had good internal consistency (Cronbach $\alpha = .69$ based on a sample of 327 controls; Cronbach $\alpha = .85$ based on a sample of 492 patients with schizophrenia). Each component raw test score was converted to a z score (mean = 0, SD = 1) based on norms established using 488 healthy controls. In addition, scores were reversed where necessary, so that a larger negative score indicates poorer performance below the mean.

At the time of initial MRI, controls underwent the same battery of assessments, including the neuropsychological battery. They were invited to return for another assessment 2 to 5 years after initial MRI.

MRI ACQUISITION, PROCESSING, AND MORPHOLOGIC BRAIN MEASURES

Images were obtained using a 1.5-T (Signa; General Electric Medical Systems, Milwaukee, Wis) MRI scanner. Three different MRI sequences were acquired for each participant. The T1-weighted spoiled GRASS (gradient recalled acquisition in the steady state) sequence was acquired with the following parameters: 1.5-mm coronal slices (n = 124); echo time, 5 milliseconds; repetition time, 24 milliseconds; flip angle, 40°; number of excitations, 2; field of view, 26 cm; matrix, 256 × 192; and echo train length, 8. The proton density- and T2-weighted images were acquired with the following parameters: 3-mm coronal slices (n = 60-64); echo time, 36 milliseconds (for proton density) or 96 milliseconds (for T2); repetition time, 3000 milliseconds; number of excitations, 1; field of view, 26 cm; matrix, 256 × 192; and echo train length, 8. All MRIs were rated for overall quality and for movement artifacts using a scale from 0 (very poor) to 4 (excellent). All MRIs in this study received quality ratings between good and excellent.

Image processing was performed on a computer workstation (Silicon Graphics Inc, Mountain View, Calif) using the lo-

cally developed BRAINS (Brain Research: Analysis of Images, Networks, and Systems) software package. Detailed descriptions of image analysis methods are provided elsewhere.³⁴⁻³⁶ In brief, the T1-weighted images were spatially normalized and resampled so that the anterior-posterior axis of the brain was realigned parallel to the anterior-posterior commissure line, and the interhemispheric fissure was aligned on the other 2 axes. The T2- and proton density-weighted images were aligned to the spatially normalized T1-weighted image using an automated image registration program.³⁷ These images were then warped into standardized stereotaxic Talairach atlas space³⁸ to generate automated measurements of the frontal, temporal, parietal, and occipital lobes; cerebellum; and subcortical regions.³⁹ To further classify tissue volumes into gray matter (GM), white matter (WM), and CSF, we used a discriminant analysis method of tissue segmentation based on automated training class selection that used data from the T1, T2, and proton density sequences.⁴⁰ This method allowed us to identify the range of values that characterized GM, WM, and CSF in our multispectral data (10-70 for CSF, 70-190 for GM, and 190-250 for WM). Each voxel was given an intensity value that was based on the weights assigned by the discriminant function and that reflected the relative combination of GM, WM, and CSF in a given voxel that allowed us to correct for partial volume.⁴⁰ Intraclass correlations for this automated tissue segmentation analysis ranged from 0.97 to 0.98. Regions of interest (ROIs) examined in the patient-control comparison included total brain tissue volume; lateral ventricle volume; cortical sulcal CSF volume; tissue and CSF volumes for the frontal, temporal, and parietal lobes; and cerebellar tissue volume.

STATISTICAL ANALYSIS

To investigate the first aim of the study, repeated-measures analysis of covariance (ANCOVA) was used to examine whether diagnostic grouping (patients vs controls) had significant interactions with longitudinal within-subject changes in each ROI. Intake and follow-up volumes for each ROI were the dependent measures (within-subject factors). The independent measure in each general linear statistical model was diagnostic grouping. Sex, height, age at intake MRI, and inter-MRI interval were entered as covariates. We chose height as a covariate instead of brain volume because height is more stable and less likely to be affected by the disorder. Age at intake MRI was used as a covariate because controls were significantly older than patients and age is known to affect brain volumes. Likewise, inter-MRI interval was also entered as a covariate because each participant had a different duration between intake and follow-up MRIs. Because there were no significant age at intake \times inter-MRI interval interaction effects on within-subject changes in brain volumes over time ($F_{1,89} \leq 1.15$; $P \geq .29$), this interaction term was not entered as a covariate. For ROIs where diagnostic grouping had significant interactions with within-subject factors of repeated measures in brain volumes (ie, brain volume changes over time in patients differed significantly from those in controls), changes in these ROIs over time expressed as a percentage of baseline ROI volume per year were further examined.

To examine cross-sectional group differences in ROIs at initial MRI, a 1-way ANCOVA was performed. In each general linear model, the dependent measure was intake MRI volume and the independent measure was diagnostic group. Sex, height, and age at intake MRI were entered as covariates. To examine cross-sectional group differences in ROIs at follow-up MRI, similar 1-way ANCOVAs were performed (with follow-up MRI volumes as the dependent measure and inter-MRI interval entered as an additional covariate).

To investigate the second study aim of how volumetric

changes may relate to functional outcome in schizophrenia, repeated-measures ANCOVA was also used to test the relationships between longitudinal within-subject changes in lateral ventricle volume and outcome grouping (good vs poor), between within-subject changes in frontal lobe volume and negative symptom severity, between within-subject changes in temporal lobe volume and positive symptom severity, and between within-subject changes in frontal lobe volume and executive functioning. In each general linear statistical model, the dependent measures were intake and follow-up volumes, with the independent measure being the respective outcome measure. Sex, height, age at intake, and inter-MRI interval were again entered as covariates. Results were considered to be statistically significant at $P \leq .05$. All statistical tests were 2-tailed.

Last, to ascertain the effects of antipsychotic drug treatment and whether this treatment may be a confounder on within-patient changes in brain volumes, exploratory analyses using repeated-measures ANCOVAs were performed with cumulative antipsychotic drug dose, total antipsychotic drug treatment duration, percentage of time treated with typical antipsychotic agents, and percentage of time treated with atypical antipsychotic agents separately as independent variables (age, sex, height, and inter-MRI interval were similarly entered as covariates).

RESULTS

LONGITUDINAL WITHIN-SUBJECT CHANGES IN ROIs BETWEEN CONTROLS AND PATIENTS

To evaluate whether volumetric changes over time differed between controls and patients, the effect of diagnostic grouping on within-subject change in each ROI was tested using repeated-measures ANCOVA (**Table 3**). Longitudinal changes in cortical sulcal CSF, frontal lobe tissue, and frontal lobe CSF volumes differed significantly between patients and controls. Patients showed greater within-subject increases in cortical sulcal CSF volumes than controls ($F_{1,90} = 4.16$; $P = .04$) (Table 3). The mean (SD) rate of increase in cortical sulcal CSF volume (expressed as a percentage of baseline volume) was 6.6% (10.87%) per year in patients vs -1.3% (9.01%) per year in controls (**Figure 1A**).

Frontal lobe tissue volume increased over time in controls, whereas patients showed a mean decrease ($F_{1,90} = 3.89$; $P = .05$) (Table 3). The reciprocal increase in frontal lobe CSF volume in patients was significantly larger than that in controls ($F_{1,90} = 10.13$; $P = .002$). The mean (SD) rates of change in frontal lobe CSF volume were -1.4% (11.46%) per year in controls and 9.1% (12.71%) per year in patients (Figure 1C). Mean (SD) frontal lobe tissue volume increased by 0.8% (1.46%) per year in controls, and patients showed a decline of 0.2% (1.63%) per year (Figure 1B). This differential change in frontal lobe tissue volume was further explored by examining GM and WM volumes. Patients had a mean (SD) reduction in frontal lobe WM volume from 174.6 (19.61) cm³ at the intake MRI to 173.6 (19.93) cm³ at the follow-up MRI compared with an increase in controls from 186.9 (22.24) cm³ at the intake MRI to 191.1 (24.08) cm³ at the follow-up MRI (within-subject effect of diagnostic grouping, $F_{1,90} = 5.57$; $P = .02$). Mean (SD) changes in frontal lobe GM volume did not differ significantly between patients (intake MRI, 266.7 [24.50] cm³; follow-up MRI, 266.4

Table 3. Comparison of MRI Brain Volumes Between Controls and Patients at Intake and Follow-up and the Effect of Diagnostic Grouping on Within-Subject Change in Regions of Interest Over Time

Brain Region of Interest	Brain Volume, Mean (SD), cm ³ *				Diagnostic Grouping	
	Controls (n = 23)		Patients (n = 73)		F _{1,90} †	P Value
	Intake	Follow-up	Intake	Follow-up		
Total brain tissue	1389.1 (112.1)	1394.8 (107.1)	1314.0 (101.7)	1313.8 (106.6)	0.54	.46
Lateral ventricles	16.8 (8.4)	17.0 (8.4)	16.7 (6.1)	17.6 (6.5)	1.22	.27
Cortical sulcal CSF	74.8 (33.2)	75.9 (35.8)	72.7 (33.9)	83.8 (39.7)	4.16	.04
Frontal lobe tissue	468.5 (42.3)	475.8 (41.9)	441.2 (38.7)	440.0 (40.8)	3.89	.05
Frontal lobe CSF	46.3 (22.5)	45.9 (21.1)	42.6 (20.3)	52.1 (26.3)	10.13	.002
Temporal lobe tissue	236.7 (21.5)	238.2 (19.7)	224.0 (18.4)	225.6 (19.0)	0.00	.99
Temporal lobe CSF	9.9 (4.4)	9.7 (4.1)	10.6 (5.1)	10.9 (4.6)	0.17	.68
Parietal lobe tissue	258.5 (24.6)	267.8 (26.7)	248.5 (22.6)	256.0 (20.4)	0.47	.49
Parietal lobe CSF	14.9 (7.5)	16.8 (8.6)	15.6 (9.2)	17.6 (9.8)	0.02	.90
Cerebellar tissue	148.1 (15.0)	139.5 (13.9)	138.9 (18.2)	134.0 (18.8)	2.08	.15

Abbreviations: CSF, cerebrospinal fluid; MRI, magnetic resonance imaging.

*Adjusted for sex, height, age, and inter-MRI interval.

†Repeated-measures analysis of covariance, with sex, height, age, and inter-MRI interval as covariates.

[26.88] cm³) and controls (intake MRI, 281.6 [24.53] cm³; follow-up MRI, 284.7 [22.00] cm³) (F_{1,90}=0.89; P=.35).

There were no differential changes between patients and controls regarding total brain tissue, lateral ventricles, temporal lobe tissue, temporal lobe CSF, parietal lobe tissue, parietal lobe CSF, or cerebellar tissue volumes (Table 3).

CROSS-SECTIONAL BETWEEN-GROUP DIFFERENCES IN ROIs

At initial MRI, patients had significantly smaller total brain tissue volume (F_{1,95}=8.37; P=.005), smaller frontal lobe tissue volume (F_{1,95}=7.53; P=.007), smaller temporal lobe tissue volume (F_{1,95}=6.77; P=.01), and smaller cerebellar tissue volume (F_{1,95}=4.27; P=.04) than controls. No statistically significant differences were found in lateral ventricles, cortical sulcal CSF, frontal lobe CSF, temporal lobe CSF, parietal lobe tissue, or parietal lobe CSF volumes between patients and controls at initial MRI (F_{1,95}≤3.00 and P≥.09 for all).

At follow-up MRI, patients had significantly smaller total brain tissue volume (F_{1,95}=9.17; P=.003), smaller frontal lobe tissue volume (F_{1,95}=12.08; P<.001), smaller temporal lobe tissue volume (F_{1,95}=6.94; P=.01), and smaller parietal lobe tissue volume (F_{1,95}=4.60; P=.03) than controls. No statistically significant differences were found in lateral ventricles, cortical sulcal CSF, frontal lobe CSF, temporal lobe CSF, parietal lobe CSF, or cerebellar tissue volumes between patients and controls at follow-up MRI (F_{1,95}≤1.49 and P≥.22 for all).

RELATIONSHIPS BETWEEN LONGITUDINAL VOLUMETRIC CHANGES AND OUTCOME

Based on the absence of positive symptom remission in the 6 months preceding follow-up MRI, 27 (39%) of 70 patients were categorized as having poor outcome. Outcome grouping had a significant effect on within-subject change in lateral ventricle volume (F_{1,64}=3.86; P=.05). Patients with poor outcome had greater mean

(SD) ventricular enlargement over time (3.7% [6.46%] per year) vs those with good outcome (0.9% [6.09%] per year) (**Figure 2A**).

There were significant effects of negative symptom severity on within-subject changes in frontal lobe WM (F_{1,64}=8.16; P=.006) and frontal lobe CSF (F_{1,64}=3.99; P=.05) volumes but not in frontal lobe GM volume (F_{1,64}=1.19; P=.28). Greater negative symptom severity during the inter-MRI interval was associated with greater decline in frontal lobe WM volume (Pearson r=-0.31; n=70; P=.01) (Figure 2B) and with greater enlargement in frontal lobe CSF volume (Pearson r=0.44; n=70; P<.001) (Figure 2C). There were no significant effects of positive symptom severity on longitudinal changes in temporal lobe tissue or temporal lobe CSF volumes (F_{1,64}≤1.48 and P≥.23 for all).

The fourth measure of outcome was executive functioning assessed using a summed z score average of 7 variables from the neuropsychological battery administered at the time of follow-up MRI. As a group, patients had mild impairment in executive functioning at the time of follow-up (mean [SD] z score=-0.62 [0.76]). There was a significant effect of executive functioning on within-subject changes in frontal lobe GM volume (F_{1,67}=4.97; P=.03) and on frontal lobe WM volume (F_{1,67}=4.32; P=.04). Impairment in executive functioning was associated with longitudinal reductions in frontal lobe GM and WM volumes (Pearson r=0.26 and 0.24, respectively; n=72; P≤.04) (Figure 2D and E). There were no significant effects of executive functioning on frontal lobe CSF volume (F_{1,67}=1.06; P=.31).

EFFECTS OF ANTIPSYCHOTIC DRUG TREATMENT ON VOLUMETRIC CHANGES

As this is a naturalistic longitudinal study, the choice of antipsychotic drug treatment, which included typical antipsychotic agents, clozapine, and the newer atypical agents (ie, olanzapine, quetiapine fumarate, risperidone, and ziprasidone hydrochloride), was left to the patient and his or her treating psychiatrist. After intake into

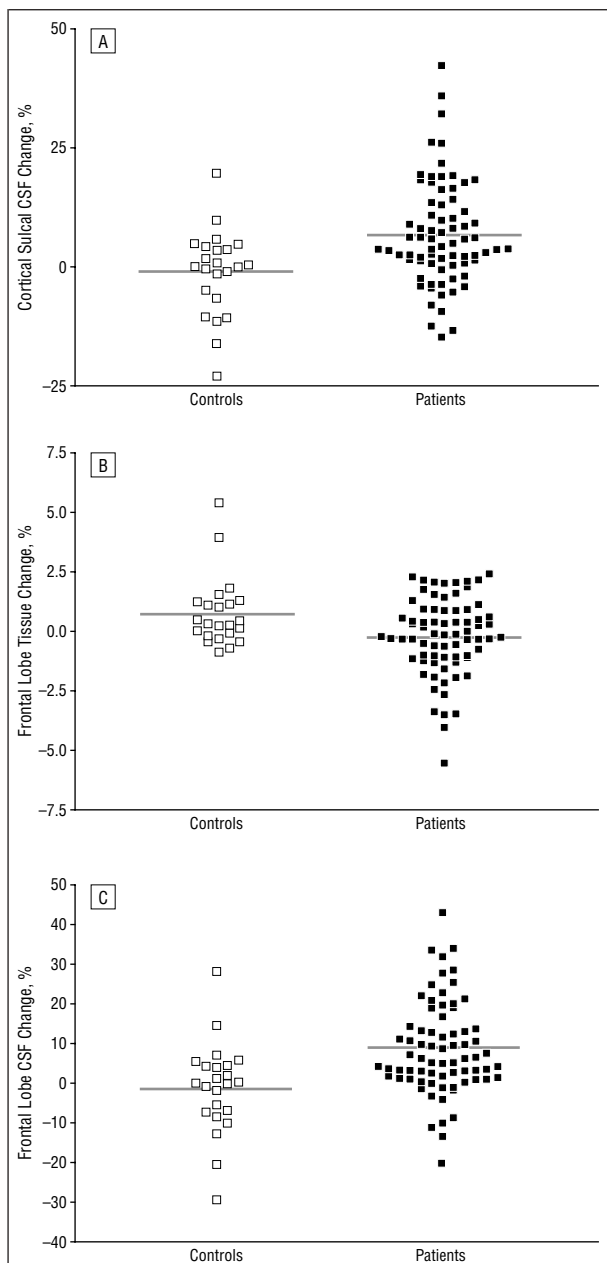


Figure 1. Mean within-subject changes in brain regions in which patients and controls differed significantly. Volume change is calculated as follow-up minus baseline expressed as a percentage of baseline volume per year. A, Cortical sulcal cerebrospinal fluid (CSF) volume increased in patients and decreased in controls (6.6% per year vs -1.3% per year; $F_{1,90}=4.16$; $P=.04$). B, Frontal lobe tissue volume increased in controls and decreased in patients (0.8% per year vs -0.2% per year; $F_{1,90}=3.89$; $P=.05$). C, Frontal lobe CSF volume increased in patients and decreased in controls (9.1% per year vs -1.4% per year; $F_{1,90}=10.13$; $P=.002$).

the study, patients received antipsychotic drug treatment for most of the time between MRIs (mean 83.5% of inter-MRI duration). Thirty-eight patients received antipsychotic drug treatment throughout the entire inter-MRI interval: 7 patients received typical antipsychotic drug treatment only, 20 received the newer atypical antipsychotic agents only, and 11 received combinations of typical and newer atypical antipsychotic medications. Fifteen patients had required treatment with clozapine. The sample was mostly treated with the newer atypical anti-

psychotic agents during the inter-MRI interval (mean [SD] duration of treatment with newer atypical antipsychotic agents, 61.7% [38.9%] of antipsychotic drug treatment duration; of treatment with typical antipsychotics, 27.7% [34.6%]; and of treatment with clozapine, 10.6% [23.7%]). The mean (SD) total cumulative antipsychotic drug dose during the inter-MRI period was 556 117.1 (494 284.5) chlorpromazine-mg equivalents, or 462.2 chlorpromazine-mg equivalents per day. Antipsychotic drug treatment compliance was generally good (mean [SD], 1.90 [0.81]; rated on a 5-point scale: 1 indicates excellent; 2, good; 3, fair; 4, poor; and 5, noncompliant).

To ascertain whether antipsychotic medication treatment may be a confounder on within-patient changes in brain volumes, repeated-measures ANCOVAs were examined with cumulative antipsychotic drug dose as the independent variable (age, sex, height, and inter-MRI interval were similarly entered as covariates). The same analysis was repeated separately with total antipsychotic drug treatment duration, percentage of time treated with typical antipsychotic drugs, and percentage of time treated with atypical antipsychotic drug as the independent variable. There were no significant effects from these 4 treatment measures on any of the ROIs ($F_{1,65} \leq 2.64$; $P \geq .11$).

COMMENT

This is the largest study to date, to our knowledge, using serial high-resolution MRIs to assess whether longitudinal structural brain changes in schizophrenia differ from the usual age-related trajectory. We found accelerated enlargements in cortical sulcal CSF spaces early in the course of schizophrenia. Instead of the usual trajectory of volume enlargement, patients showed progressive decrement in frontal lobe WM volume over time. A reciprocal increase in frontal lobe CSF volume also occurred at a more rapid rate than in controls. These brain volume changes seem to be most evident in the frontal lobes, and they correlate with functional impairment. Progressive decrement in frontal lobe WM volume and enlargement in frontal lobe CSF volume were associated with greater negative symptom severity, and reductions in frontal lobe GM and WM volumes correlated with poorer executive functioning. Patients with poor outcome (ie, those without remission of positive symptoms) had greater lateral ventricular enlargement over time than those with a good outcome. Longitudinal changes in temporal lobe volumes, however, did not predict positive symptom severity, as we had hypothesized a priori.

To the best of our knowledge, no previous longitudinal MRI studies have reported progressive cortical sulcal CSF volume enlargement in schizophrenic patients. Enlargements in CSF volume over time may be indicative of progressive brain tissue volume reduction.⁴¹⁻⁴³ Intracranial volume is stable after fusion of the cranial sutures, and CSF fills in for brain tissue loss. However, longitudinal changes in total brain tissue volume in our study did not differ significantly between patients and controls, although patients had significantly greater enlargements in cortical sulcal CSF volume over time. The finding that schizophrenic patients show greater pro-

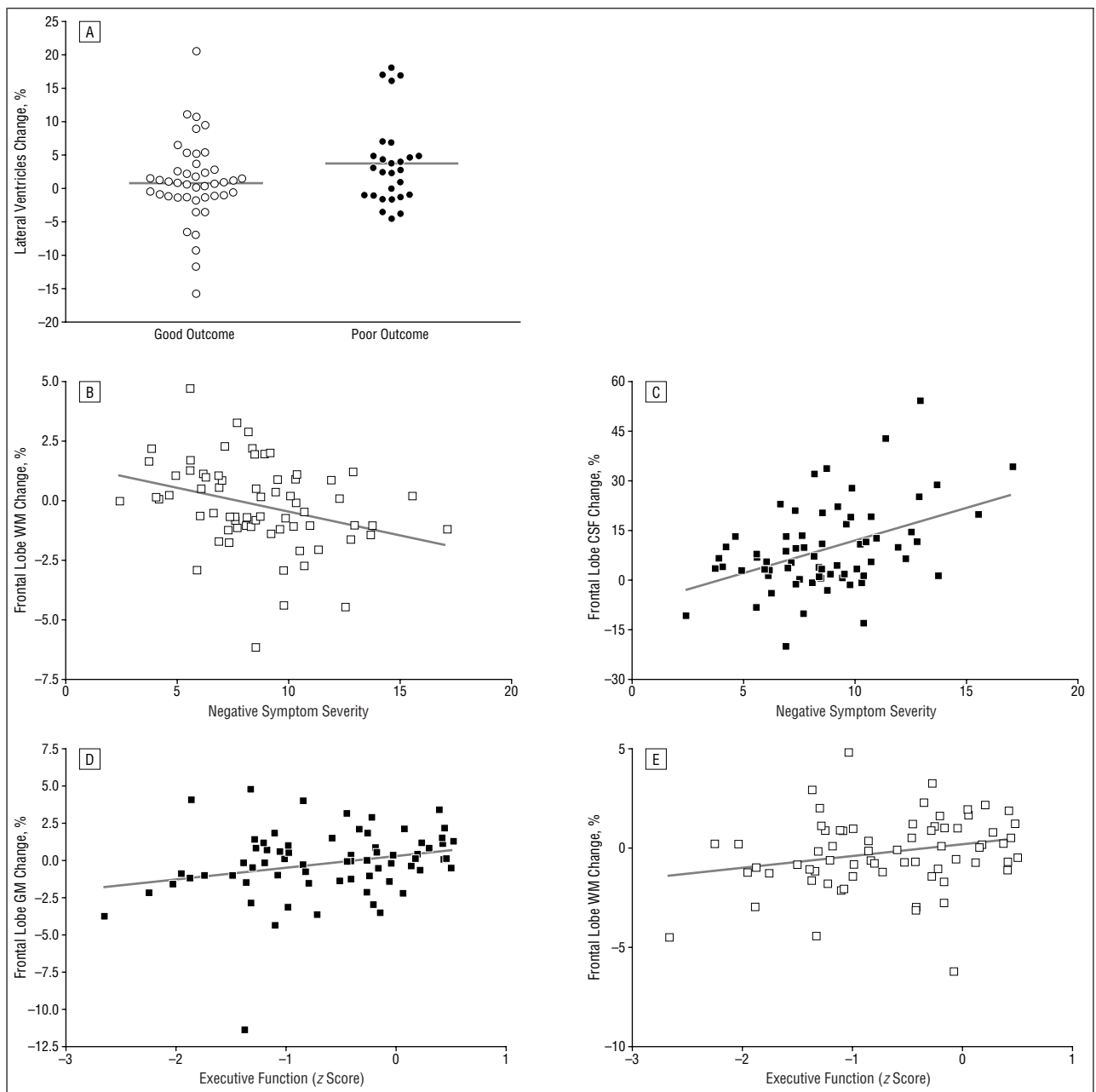


Figure 2. Relationships between longitudinal changes in brain volumes and outcome in schizophrenia. Volume change is calculated as follow-up minus baseline expressed as a percentage of baseline volume per year. A, Lateral ventricular volume enlargement was significantly greater in patients with poor outcome than in those with good outcome (3.7% per year vs 0.9% per year; $F_{1,64}=3.86$; $P=.05$). B, Greater negative symptom severity was significantly correlated with a greater reduction in frontal lobe white matter (WM) volume (Pearson $r=-0.31$; $n=70$; $P=.01$). C, Greater negative symptom severity was significantly correlated with greater enlargement in frontal lobe cerebrospinal fluid (CSF) volume ($r=0.44$; $N=70$; $P<.001$). D, Impairment in executive functioning was associated with a greater reduction in frontal lobe gray matter (GM) volume ($r=0.26$; $n=72$; $P=.03$). E, Impairment in executive functioning was associated with a greater reduction in frontal lobe WM volume ($r=0.24$; $n=72$; $P=.04$).

gressive reduction in total brain tissue volume than controls is somewhat mixed among the longitudinal neuroimaging studies to date. Two prospective longitudinal studies^{16,20} on first-episode schizophrenic patients have reported a differential reduction in total brain tissue volume, but other studies,^{17,18,44} including the present study, have not found patients to differ from controls. The study by Cahn et al²⁰ on first-episode schizophrenia over a 1-year period and a series of studies^{24,27,45} on childhood-onset schizophrenic patients have found progressive reductions in total GM volume in

schizophrenic patients. Similar to total brain tissue volume, the finding of progressive enlargement in lateral ventricular volume during follow-up has been similarly contradictory. Some studies^{16,20-22} have reported progressive ventricular enlargement, whereas others,^{15,17,18,44,46} including this study, have not.

Indeed, the literature on progressive volumetric brain changes during the longitudinal course of schizophrenia seems to be conflicting, and “no 2 (longitudinal) studies have found the same pattern of changes across all of these measures, and each study seems to have its own

unique combination of results.”^{47(p555)} However, although individual studies may report different combinations of subregions undergoing progressive volumetric changes, the growing list of longitudinal MRI studies in first-episode patients,¹⁶⁻²⁰ chronic patients,²¹ and childhood-onset patients²²⁻²⁷ provides increasingly convergent evidence that structural brain deficits in schizophrenia may be progressive. Several factors may have led to this “unique combination of results” in each of these longitudinal studies: heterogeneity of schizophrenia, differences in imaging parameters, image analysis and processing, reproducibility of repeated MRIs, and small sample size with inadequate power.

Although our study has the largest sample to date, it has its own limitations as well. Comparatively fewer controls than schizophrenic patients, an older control group, variability in inter-MRI interval, and naturalistic, nonstandardized antipsychotic drug treatment may have affected our findings. Although controls were significantly older than patients, it is unlikely that a mean difference of 2.4 years during early adulthood would affect longitudinal changes in brain volumes between patient and control groups. Furthermore, the distributions of patients and controls by decade of age (ie, 16-25 years and 26-35 years) were no different, and there were no significant age at initial MRI \times inter-MRI interval interaction effects on within-subject changes in brain volumes. Age at intake MRI and inter-MRI interval were entered as covariates in our analyses to statistically “control” for these differences. We also explored the potential effect of antipsychotic treatment on longitudinal changes in brain volumes, and we did not find any significant effects from any of the 4 antipsychotic drug treatment measures.

In this study, longitudinal brain morphologic changes early in the course of schizophrenia seem to be most evident in the frontal lobes. Schizophrenic patients had a mean reduction in frontal lobe WM volume and a concomitant increase in frontal lobe CSF volume over time. Controls, on the other hand, showed an increase in frontal lobe WM volume. This differential change may represent a dysmaturation process in schizophrenia, in which frontal lobe WM fails to undergo the usual trajectory of progressive myelination or increased interconnection. Previous *in vivo* MRI studies^{45,48} have indicated that cerebral WM volume increases during childhood. Normal central nervous system development proceeds in a systematic spatial sequence^{49,50} such that the frontal lobes are one of the last regions to mature.⁵¹ Cerebral WM development extends into adulthood,⁴⁸ and frontal lobe WM volume may peak as late as in the fifth decade of life in healthy individuals.⁵² This increase coincides with the period when profound cognitive development is taking place and may result from myelination or increased interconnectivity between cerebral regions. Myelin sheath thickness and the number of myelin lamellae have been reported to increase with age in primate brains, suggesting that oligodendrocytes actively produce myelin during the normal aging process.⁵³ Although we are beginning to better understand these late maturational events in the central nervous system, the pathogenetic changes and mechanisms that underlie the progressive frontal lobe WM

volume reduction in schizophrenia are unclear. Defects in oligodendrocytes and myelin lamellae reported in the prefrontal cortex of schizophrenic patients⁵⁴⁻⁵⁶ may explain this progressive decrement in frontal lobe WM volume. There is also an emerging body of literature from MRI spectroscopy and diffusion tensor imaging studies^{57,58} implicating WM abnormalities in schizophrenia.

Our findings also indicate that progressive changes in brain volumes, again predominantly in the frontal lobes, correlate with functional outcome in schizophrenia. Patients with a more severe and enduring form of the disorder were more likely to show longitudinal alterations in brain volumes. We replicated the association between poor positive symptom remission and progressive lateral ventricular enlargement, which has been reported in previous longitudinal MRI studies.^{18,20,28,59} In addition, we found that greater negative symptom severity correlated with longitudinal reduction in frontal lobe WM volume and progressive enlargement in frontal lobe CSF volume. Patients with poor executive functioning at follow-up showed greater declines in frontal lobe GM and WM volumes over time. These functional correlates for longitudinal reductions in frontal lobe WM and GM volumes are consistent with those of previous cross-sectional MRI studies.⁶⁰⁻⁶⁶

What is the mechanism that produces these progressive changes? During the past 15 years, one of the most prevailing theories regarding the pathogenesis of schizophrenia has been that it is a neurodevelopmental disorder. This hypothesis posits that abnormal genetic or epigenetic factors interfere with early brain development (neurulation, cellular proliferation, migration, differentiation, and synaptogenesis).^{67,68} Later brain development processes (eg, apoptosis and synaptic pruning) or other neuropathological events (eg, stress) interact with the already aberrant neuropathological events to result in symptoms and signs of schizophrenia.

Although a large body of literature has been regarded as evidence for the neurodevelopmental hypothesis,⁶⁹ certain aspects of schizophrenia, including progressive brain changes of the magnitude observed in the present study, may be difficult to attribute to aberrant neurodevelopment.⁷⁰ Changes that progress over time are usually considered to represent “neurodegeneration” or “atrophy,” as originally posited by Kraepelin et al⁷¹ when they identified this illness and called it “dementia praecox.” However, gliosis, considered to be the hallmark of neuronal death in neurodegenerative disorders, is characteristically absent in schizophrenia. Absence of gliosis has been the strongest evidence against considering schizophrenia to have a neurodegenerative component. One alternative model that may explain our results is that of a “progressive neurodevelopmental disorder.”⁷⁰ According to this model, schizophrenia occurs as a consequence of multiple aberrations in the process of brain development, with some occurring during fetal life or early childhood (“early neurodevelopment”), whereas others occur during adolescence and young adulthood (“late neurodevelopment”). Our data suggest that the late neurodevelopmental mechanisms, which were already active during the months before the onset of clinical symptoms, may continue to exert their damaging effects after

onset and during the early years of the illness, which characteristically is a chronic lifetime condition. The developmental neurobiological processes that explain these serial changes remains a puzzle, however.

Given that brain changes continue to progress and tissue loss persists, the search for treatments that may arrest progression assumes great importance. Our findings indicate that current treatments do not arrest the progression of the illness. Ongoing changes occur in the brains of schizophrenic patients during the initial years after diagnosis, even when they had received antipsychotic drug treatment during much of that period. Although antipsychotic drug therapy reduces the risk for relapse of psychotic symptoms,⁷² whether these medications actually modify other aspects of the course of schizophrenia remains a topic of debate.⁷³⁻⁷⁵ The results of the present study indicate that the medications currently used cannot modify an injurious process occurring in the brain, which is the underlying basis of symptoms and other aspects of outcome and should be the ultimate target of treatment. We found that progressive volumetric brain changes were occurring despite ongoing antipsychotic drug treatment.

Although it is reasonable to assume that longitudinal volumetric changes result primarily from ongoing pathogenetic process(es) of the illness, it is important to consider other causes not directly related to the neurobiology of schizophrenia. Differences arising from chronic illness, including poor nutrition,⁷⁶ fluid imbalance,⁷⁷ and diminished social and environmental stimuli,⁷⁸ may be potential mediators for longitudinal brain changes as well. The brain, much like other organ systems, responds to environmental effects, and neuroplastic changes occur throughout life.⁷⁹ Therefore, the longitudinal volumetric changes observed in our study probably resulted from a combination of factors. In addition, given the heterogeneity of schizophrenia, different pathogenetic processes may be associated with the progressive volumetric changes in different patients.

In conclusion, our findings suggest that there are ongoing changes in the brains of schizophrenic patients during the initial years after diagnosis despite concurrent antipsychotic drug treatment. Progression in volumetric deficits seems to be most prominent in the frontal lobes. Late developmental processes and neural plasticity may act alone or in combination with disrupted early neurodevelopment to bring about such progressive brain changes in schizophrenia.

Submitted for publication June 14, 2002; final revision received December 31, 2002; accepted January 9, 2003.

This study was supported in part by grants MH31593, MH40856, and MH43271 from the National Institute of Mental Health, Bethesda, Md.

This study was presented in part at the 40th Annual Meeting of the American College of Neuropsychopharmacology; December 9, 2001; Waikoloa, Hawaii; and at the XI Biennial Winter Workshop on Schizophrenia; February 23, 2002; Davos, Switzerland.

Corresponding author and reprints: Beng-Choon Ho, MRCPsych, Department of Psychiatry, University of Iowa

College of Medicine, 200 Hawkins Dr, Iowa City, IA 52252 (e-mail: beng-ho@uiowa.edu).

REFERENCES

- Johnstone EC, Crow TJ, Frith CD, Husband J, Kreef L. Cerebral ventricular size and cognitive impairment in chronic schizophrenia. *Lancet*. 1976;2:924-926.
- Andreasen NC, Nasrallah HA, Dunn V, Olson SC, Grove WM, Ehrhardt JC, Coffman JA, Cosslett JH. Structural abnormalities in the frontal system in schizophrenia: a magnetic resonance imaging study. *Arch Gen Psychiatry*. 1986;43:136-144.
- Shenton ME, Dickey CC, Frumin M, McCarley RW. A review of MRI findings in schizophrenia. *Schizophr Res*. 2001;49:1-52.
- Andreasen NC, Paradiso S, O'Leary DS. "Cognitive dysmetria" as an integrative theory of schizophrenia: a dysfunction in cortical-subcortical-cerebellar circuitry? *Schizophr Bull*. 1998;24:203-218.
- Lewis DA. Distributed disturbances in brain structure and function in schizophrenia. *Am J Psychiatry*. 2000;157:1-2.
- Staal WG, Hulshoff Pol HE, Kahn RS. Outcome of schizophrenia in relation to brain abnormalities. *Schizophr Bull*. 1999;25:337-348.
- Keshavan MS, Montrose DM, Pierri JN, Dick EL, Rosenberg D, Talagala L, Sweeney JA. Magnetic resonance imaging and spectroscopy in offspring at risk for schizophrenia: preliminary studies. *Prog Neuropsychopharmacol Biol Psychiatry*. 1997;21:1285-1295.
- Sharma T, Lancaster E, Lee D, Lewis S, Sigmundsson T, Takei N, Gurling H, Barta P, Pearson G, Murray R. Brain changes in schizophrenia: volumetric MRI study of families multiply affected with schizophrenia—the Maudsley Family Study 5. *Br J Psychiatry*. 1998;173:132-138.
- Cannon TD, van Erp TG, Huttunen M, Lonnqvist J, Salonen O, Valanne L, Poutanen VP, Standertskjold-Nordenstam CG, Gur RE, Yan M. Regional gray matter, white matter, and cerebrospinal fluid distributions in schizophrenic patients, their siblings, and controls. *Arch Gen Psychiatry*. 1998;55:1084-1091.
- Seidman LJ, Faraone SV, Goldstein JM, Goodman JM, Kremen WS, Toomey R, Tourville J, Kennedy D, Makris N, Caviness VS, Tsuang MT. Thalamic and amygdala-hippocampal volume reductions in first-degree relatives of patients with schizophrenia: an MRI-based morphometric analysis. *Biol Psychiatry*. 1999;46:941-954.
- Schreiber H, Baur-Seack K, Kornhuber HH, Wallner B, Friedrich JM, De Winter IM, Born J. Brain morphology in adolescents at genetic risk for schizophrenia assessed by qualitative and quantitative magnetic resonance imaging. *Schizophr Res*. 1999;40:81-84.
- Staal WG, Hulshoff Pol HE, Schnack HG, Hoogendoorn ML, Jellema K, Kahn RS. Structural brain abnormalities in patients with schizophrenia and their healthy siblings. *Am J Psychiatry*. 2000;157:416-421.
- Lawrie SM, Whalley HC, Abukmeil SS, Kestelman JN, Donnelly L, Miller P, Best JJ, Owens DG, Johnstone EC. Brain structure, genetic liability, and psychotic symptoms in subjects at high risk of developing schizophrenia. *Biol Psychiatry*. 2001;49:811-823.
- Nopoulos P, Torres I, Flaum M, Andreasen NC, Ehrhardt JC, Yuh WT. Brain morphology in first-episode schizophrenia. *Am J Psychiatry*. 1995;152:1721-1723.
- Nasrallah HA, Olson SC, McCalley-Whitters M, Chapman S, Jacoby CG. Cerebral ventricular enlargement in schizophrenia: a preliminary follow-up study. *Arch Gen Psychiatry*. 1986;43:157-159.
- DeLisi LE, Sakuma M, Tew W, Kushner M, Hoff AL, Grimson R. Schizophrenia as a chronic active brain process: a study of progressive brain structural change subsequent to the onset of schizophrenia. *Psychiatry Res*. 1997;74:129-140.
- Gur RE, Cowell P, Turetsky BI, Gallacher F, Cannon T, Bilker W, Gur RC. A follow-up magnetic resonance imaging study of schizophrenia: relationship of neuroanatomical changes to clinical and neurobehavioral measures. *Arch Gen Psychiatry*. 1998;55:145-152.
- Lieberman J, Chakos M, Wu H, Alvir J, Hoffman E, Robinson D, Bilder R. Longitudinal study of brain morphology in first episode schizophrenia. *Biol Psychiatry*. 2001;49:487-499.
- Wood SJ, Velakoulis D, Smith DJ, Bond D, Stuart GW, McGorry PD, Brewer WJ, Bridle N, Eritaia J, Desmond P, Singh B, Copolov D, Pantelis C. A longitudinal study of hippocampal volume in first episode psychosis and chronic schizophrenia. *Schizophr Res*. 2001;52:37-46.
- Cahn W, Pol HE, Lems EB, van Haren NE, Schnack HG, van der Linden JA, Schothorst PF, van Engeland H, Kahn RS. Brain volume changes in first-episode schizophrenia: a 1-year follow-up study. *Arch Gen Psychiatry*. 2002;59:1002-1010.
- Mathalon DH, Sullivan EV, Lim KO, Pfefferbaum A. Progressive brain volume changes and the clinical course of schizophrenia in men: a longitudinal magnetic resonance imaging study. *Arch Gen Psychiatry*. 2001;58:148-157.
- Rapoport JL, Giedd J, Kumra S, Jacobsen L, Smith A, Lee P, Nelson J, Hamburger S. Childhood-onset schizophrenia: progressive ventricular change during adolescence. *Arch Gen Psychiatry*. 1997;54:897-903.
- Jacobsen LK, Giedd JN, Castellanos FX, Vaituzis AC, Hamburger SD, Kumra S, Lenane MC, Rapoport JL. Progressive reduction of temporal lobe structures in childhood-onset schizophrenia. *Am J Psychiatry*. 1998;155:678-685.
- Rapoport JL, Giedd JN, Blumenthal J, Hamburger S, Jeffries N, Fernandez T, Nicolson R, Bedwell J, Lenane M, Zijdenbos A, Paus T, Evans A. Progressive cortical change during adolescence in childhood-onset schizophrenia: a longitudinal magnetic resonance imaging study. *Arch Gen Psychiatry*. 1999;56:649-654.

25. Giedd JN, Jeffries NO, Blumenthal J, Castellanos FX, Vaituzis AC, Fernandez T, Hamburger SD, Liu H, Nelson J, Bedwell J, Tran L, Lenane M, Nicolson R, Rapoport JL. Childhood-onset schizophrenia: progressive brain changes during adolescence. *Biol Psychiatry*. 1999;46:892-898.
26. Kumra S, Giedd JN, Vaituzis AC, Jacobsen LK, McKenna K, Bedwell J, Hamburger S, Nelson JE, Lenane M, Rapoport JL. Childhood-onset psychotic disorders: magnetic resonance imaging of volumetric differences in brain structure. *Am J Psychiatry*. 2000;157:1467-1474.
27. Thompson PM, Vidal C, Giedd JN, Gochman P, Blumenthal J, Nicolson R, Toga AW, Rapoport JL. Mapping adolescent brain change reveals dynamic wave of accelerated gray matter loss in very early-onset schizophrenia. *Proc Natl Acad Sci U S A*. 2001;98:11650-11655.
28. Nair TR, Christensen JD, Kingsbury SJ, Kumar NG, Terry WM, Garver DL. Progression of cerebroventricular enlargement and the subtyping of schizophrenia. *Psychiatry Res*. 1997;74:141-150.
29. Andreasen NC, Flaum M, Arndt S. The Comprehensive Assessment of Symptoms and History (CASH): an instrument for assessing diagnosis and psychopathology. *Arch Gen Psychiatry*. 1992;49:615-623.
30. Flaum MA, Andreasen NC, Arndt S. The Iowa Prospective Longitudinal Study of Recent-Onset Psychoses. *Schizophr Bull*. 1992;18:481-490.
31. Andreasen NC. *PSYCH-BASE*. Iowa City: University of Iowa; 1989.
32. Andreasen NC. *Scale for Assessment of Negative Symptoms (SANS)*. Iowa City: University of Iowa; 1983.
33. Andreasen NC. *Scale for Assessment of Positive Symptoms (SAPS)*. Iowa City: University of Iowa; 1984.
34. Andreasen NC, Cohen G, Harris G, Cizadlo T, Parkkinen J, Rezaei K, Swayze VW 2nd. Image processing for the study of brain structure and function: problems and programs. *J Neuropsychiatry Clin Neurosci*. 1992;4:125-133.
35. Andreasen NC, Cizadlo T, Harris G, Swayze V 2nd, O'Leary DS, Cohen G, Ehrhardt J, Yuh WT. Voxel processing techniques for the anteromortem study of neuroanatomy and neuropathology using magnetic resonance imaging. *J Neuropsychiatry Clin Neurosci*. 1993;5:121-130.
36. Andreasen NC, Harris G, Cizadlo T, Arndt S, O'Leary DS, Swayze V, Flaum M. Techniques for measuring sulcal/gyral patterns in the brain as visualized through magnetic resonance scanning: BRAINPLOT and BRAINMAP. *Proc Natl Acad Sci U S A*. 1994;91:93-97.
37. Woods RP, Cherry SR, Mazziotta JC. Rapid automated algorithm for aligning and reslicing PET images. *J Comput Assist Tomogr*. 1992;16:620-633.
38. Talairach J, Tournoux P. *Co-Planar Stereotaxic Atlas of the Human Brain*. New York, NY: Thieme Medical Publishers; 1988.
39. Andreasen NC, Rajarethinam R, Cizadlo T, Arndt S, Swayze VW 2nd, Flashman LA, O'Leary DS, Ehrhardt JC, Yuh WT. Automatic atlas-based volume estimation of human brain regions from MR images. *J Comput Assist Tomogr*. 1996;20:98-106.
40. Harris G, Andreasen NC, Cizadlo T, Bailey JM, Bockholt HJ, Magnotta VA, Arndt S. Improving tissue classification in MRI: a three-dimensional multispectral discriminant analysis method with automated training class selection. *J Comput Assist Tomogr*. 1999;23:144-154.
41. Symonds LL, Archibald SL, Grant I, Zisook S, Jernigan TL. Does an increase in sulcal or ventricular fluid predict where brain tissue is lost? *J Neuroimaging*. 1999;9:201-209.
42. Woods BT, Yurgelun-Todd D. Brain volume loss in schizophrenia: when does it occur and is it progressive? *Schizophr Res*. 1991;5:202-204.
43. Woods BT, Yurgelun-Todd D, Goldstein JM, Seidman LJ, Tsuang MT. MRI brain abnormalities in chronic schizophrenia: one process or more? *Biol Psychiatry*. 1996;40:585-596.
44. James AC, Javaloyes A, James S, Smith DM. Evidence for non-progressive changes in adolescent-onset schizophrenia: follow-up magnetic resonance imaging study. *Br J Psychiatry*. 2002;180:339-344.
45. Giedd JN, Blumenthal J, Jeffries NO, Castellanos FX, Liu H, Zijdenbos A, Paus T, Evans AC, Rapoport JL. Brain development during childhood and adolescence: a longitudinal MRI study. *Nat Neurosci*. 1999;2:861-863.
46. Kemali D, Maj M, Galderisi S, Milici N, Salvati A. Ventricle-to-brain ratio in schizophrenia: a controlled follow-up study. *Biol Psychiatry*. 1989;26:756-759.
47. Weinberger DR, McClure RK. Neurotoxicity, neuroplasticity, and magnetic resonance imaging morphometry: what is happening in the schizophrenic brain? *Arch Gen Psychiatry*. 2002;59:553-558.
48. Pfefferbaum A, Mathalon DH, Sullivan EV, Rawles JM, Zipursky RB, Lim KO. A quantitative magnetic resonance imaging study of changes in brain morphology from infancy to late adulthood. *Arch Neurol*. 1994;51:874-887.
49. Benes FM, Turtle M, Khan Y, Farol P. Myelination of a key relay zone in the hippocampal formation occurs in the human brain during childhood, adolescence, and adulthood. *Arch Gen Psychiatry*. 1994;51:477-484.
50. Reiss AL, Abrams MT, Singer HS, Ross JL, Denckla MB. Brain development, gender and IQ in children: a volumetric imaging study. *Brain*. 1996;119:1763-1774.
51. Yakovlev PI, Lecours A-R. The myelogenetic cycles of regional maturation of the brain. In: Minkowski A, ed. *Regional Development of the Brain in Early Life*. Philadelphia, Pa: FA Davis Co Publishers; 1967:3-70.
52. Bartzokis G, Beckson M, Lu PH, Nuechterlein KH, Edwards N, Mintz J. Age-related changes in frontal and temporal lobe volumes in men: a magnetic resonance imaging study. *Arch Gen Psychiatry*. 2001;58:461-465.
53. Peters A, Sethares C, Killiany RJ. Effects of age on the thickness of myelin sheaths in monkey primary visual cortex. *J Comp Neurol*. 2001;435:241-248.
54. Uranova N, Orlovskaya D, Vikhrev O, Zimina I, Kolomeets N, Vostrikov V, Rachmanova V. Electron microscopy of oligodendroglia in severe mental illness. *Brain Res Bull*. 2001;55:597-610.
55. Uranova NA, Casanova MF, DeVaughn NM, Orlovskaya DD, Denisov DV. Ultrastructural alterations of synaptic contacts and astrocytes in postmortem caudate nucleus of schizophrenic patients. *Schizophr Res*. 1996;22:81-83.
56. Miyakawa T, Sumiyoshi S, Deshimaru M, Suzuki T, Tomonari H. Electron microscopic study on schizophrenia: mechanism of pathological changes. *Acta Neuropathol*. 1972;20:67-77.
57. Buchsbaum MS, Tang CY, Peled S, Gudbjartsson H, Lu D, Hazlett EA, Downhill J, Haznedar M, Fallon JH, Atlas SW. MRI white matter diffusion anisotropy and PET metabolic rate in schizophrenia. *Neuroreport*. 1998;9:425-430.
58. Lim KO, Hedehus M, Moseley M, de Crespigny A, Sullivan EV, Pfefferbaum A. Compromised white matter tract integrity in schizophrenia inferred from diffusion tensor imaging. *Arch Gen Psychiatry*. 1999;56:367-374.
59. DeLisi LE, Hoff AL, Kushner M, Caley A, Stritzke P. Left ventricular enlargement associated with diagnostic outcome of schizophreniform disorder. *Biol Psychiatry*. 1992;32:199-201.
60. Seidman LJ, Yurgelun-Todd D, Kremen WS, Woods BT, Goldstein JM, Faraone SV, Tsuang MT. Relationship of prefrontal and temporal lobe MRI measures to neuropsychological performance in chronic schizophrenia. *Biol Psychiatry*. 1994;35:235-246.
61. Wible CG, Shenton ME, Hokama H, Kikinis R, Jolesz FA, Metcalf D, McCarley RW. Prefrontal cortex and schizophrenia: a quantitative magnetic resonance imaging study. *Arch Gen Psychiatry*. 1995;52:279-288.
62. Baare WF, Hulshoff Pol HE, Hijman R, Mali WP, Viergever MA, Kahn RS. Volumetric analysis of frontal lobe regions in schizophrenia: relation to cognitive function and symptomatology. *Biol Psychiatry*. 1999;45:1597-1605.
63. Sanfilippo M, Lafargue T, Rusinek H, Arena L, Loneragan C, Laitin A, Feiner D, Rotrosen J, Wolkin A. Volumetric measure of the frontal and temporal lobe regions in schizophrenia: relationship to negative symptoms. *Arch Gen Psychiatry*. 2000;57:471-480.
64. Wible CG, Anderson J, Shenton ME, Kricun A, Hirayasu Y, Tanaka S, Levitt JJ, O'Donnell BF, Kikinis R, Jolesz FA, McCarley RW. Prefrontal cortex, negative symptoms, and schizophrenia: an MRI study. *Psychiatry Res*. 2001;108:65-78.
65. Gur RE, Cowell PE, Latshaw A, Turetsky BI, Grossman RI, Arnold SE, Bilker WB, Gur RC. Reduced dorsal and orbital prefrontal gray matter volumes in schizophrenia. *Arch Gen Psychiatry*. 2000;57:761-768.
66. Szeszko PR, Bilder RM, Lencz T, Ashtari M, Goldman RS, Reiter G, Wu H, Lieberman JA. Reduced anterior cingulate gyrus volume correlates with executive dysfunction in men with first-episode schizophrenia. *Schizophr Res*. 2000;43:97-108.
67. Murray RM, Lewis SW. Is schizophrenia a neurodevelopmental disorder [editorial]? *Br Med J Clin Res Ed*. 1987;295:681-682.
68. Weinberger DR. Implications of normal brain development for the pathogenesis of schizophrenia. *Arch Gen Psychiatry*. 1987;44:660-669.
69. Weinberger DR. On the plausibility of "the neurodevelopmental hypothesis" of schizophrenia. *Neuropsychopharmacology*. 1996;14(suppl):1S-11S.
70. Woods BT. Is schizophrenia a progressive neurodevelopmental disorder? toward a unitary pathogenetic mechanism. *Am J Psychiatry*. 1998;155:1661-1670.
71. Kraepelin E, Barclay RM, Robertson GM. *Dementia Praecox and Paraphrenia*. Edinburgh, Scotland: E&S Livingstone; 1919.
72. Gilbert PL, Harris MJ, McAdams LA, Jeste DV. Neuroleptic withdrawal in schizophrenic patients: a review of the literature. *Arch Gen Psychiatry*. 1995;52:173-188.
73. Wyatt RJ. Neuroleptics and the natural course of schizophrenia. *Schizophr Bull*. 1991;17:325-351.
74. Wyatt RJ. Antipsychotic medication and the long-term course of schizophrenia. In: Shrikri CL, Nasrallah HA, eds. *Contemporary Issues in the Treatment of Schizophrenia*. Washington, DC: American Psychiatric Press; 1995:385-410.
75. Carpenter WT Jr. The risk of medication-free research. *Schizophr Bull*. 1997;23:11-18.
76. Swayze VW II, Andersen A, Arndt S, Rajarethinam R, Fleming F, Sato Y, Andreasen NC. Reversibility of brain tissue loss in anorexia nervosa assessed with a computerized Talairach 3-D proportional grid. *Psychol Med*. 1996;26:381-390.
77. Kirch DG, Bigelow LB, Weinberger DR, Lawson WB, Wyatt RJ. Polydipsia and chronic hyponatremia in schizophrenic inpatients. *J Clin Psychiatry*. 1985;46:179-181.
78. Diamond MC. Response of the brain to enrichment. *An Acad Bras Cienc*. 2001;73:211-220.
79. Eriksson PS, Perfilieva E, Bjork-Eriksson T, Alborn AM, Nordborg C, Peterson DA, Gage FH. Neurogenesis in the adult human hippocampus. *Nat Med*. 1998;4:1313-1317.
80. Hollingshead AB, Redlich FC. *Social Class and Mental Illness: A Community Study*. New York, NY: John Wiley & Sons Inc; 1958.